

Cephalohematoma after Cardiopulmonary Bypass

Authors: TS Sangari, ML Schmitz, SC Faulkner, LM Zabala, S Ullah, WB Watkins, CE Johnson, M Imamura, RDB Jaquiss

Affiliation: Arkansas Children's Hospital & the University of Arkansas for Medical Sciences

Introduction: We report an unusual case of cephalohematoma 13 hours after open heart surgery.

Case report: A 1 year-old, term birth, 9.8 kg child with Down syndrome and Tetralogy of Fallot with pulmonary atresia was admitted for continuation of surgical correction. A right modified Blalock-Taussig and a later left modified shunt were performed during first months of life. The child had been doing well since the second shunt placement and was on no medications other than daily aspirin. Other than obvious cardiac findings, preoperative physical examination was normal and the hematocrit (Hct) was 49.5% with platelet count of 384,000. The child underwent inhalation induction with oxygen, nitrous oxide and sevoflurane, placement of an endotracheal tube, and arterial and central venous monitors. A pre-heparin thromboelastograph (TEG) (TEG[®] Hemostatic Analyzer, Haemoscope Corp., Niles, IL) (Figure 1) run in a heparinase cup indicated a prolonged R of 15.8min (normal 4-8 min), an alpha angle of 40° (normal 47°-74°), K of 4.3 sec (normal 1-4 sec), MA of 57.8 mm (normal 55-73 mm), and an activated clotting time (Medtronic, Minneapolis, MN) of 108 sec. Prior to cardiopulmonary bypass (CPB), there were no clinical signs of excessive bleeding. Prior to CPB, 4000 units of heparin raised the ACT to greater than 999 sec. The ventricular septal defect was repaired and a right ventricle to pulmonary artery conduit was placed. After 2 hours of CPB, a second TEG suggested pancytopenia. The patient separated from CPB (157 min CPB and 68 min cross-clamp time) with dopamine (5 mcg/kg/min), norepinephrine (0.1 mcg/kg/min) and milrinone (0.5 mcg/kg/min) infusions. Modified ultrafiltration increased the Hct from 36% to 46%. Heparin was reversed with protamine and yielding an ACT of 109 seconds. At the end of the surgery, a third TEG (Figure 2) showed a prolonged values for R of 14.3 min, K of 5.2 min, alpha angle of 44°, and an MA approaching normal range (test terminated early). Laboratory testing on arrival showed a platelet count of 98 K/ μ L, fibrinogen 97.5 mg/dL, prothrombin time 16.1 seconds, activated partial thromboplastin time 77.4 sec, and international normalized ratio of 1.7. Based on TEG results, the child was transfused with 55 ml of cryoprecipitate, raising the fibrinogen level to 249.8 mg/dL. The child spent the first postoperative night intubated, ventilated, and with hemodynamic support with dopamine and norepinephrine infusions. Despite chest tube drainage of only 83ml and only 158 ml of Tenckhoff peritoneal drainage (total 241 ml), the Hct dropped from 45.7 to 38.1% in first 4 postoperative hours and to 32.6% in following four hours. In the first 8 hours, 50 ml of 5% albumin, 55 ml of cryoprecipitate and 383 ml of crystalloid. Tenckhoff drainage were 332 ml in the first 8 hours. During postoperative hours 9-12, the child's blood pressure became labile, but was stabilized with an increase in the dopamine infusion to 7.5 mcg/kg/min and transfusion of 100 ml of packed red blood cells and 50 ml of 5% albumin. At the 13th postoperative hour, a boggy edematous area was noted on the patient's right side of head. An increase in head circumference to 49cm from the preoperative measurement of 46.2 cm admission was noted. The mass measured 10 cm in diameter and approximately 1.5 cm from surface to skull by palpation. A Roentgenogram of the skull showed soft-tissue swelling over the right parietal area with non-depressed skull fracture of right parietal bone extending from coronal to lambdoid suture (Figure 3). Computerized tomography showed normal intracranial contents with no evidence of hemorrhage or mass effect. The child received 65ml fresh frozen plasma after the skull film and another 65 ml was transfused 8 hours later. We asked the parents about recent trauma the child might have suffered and they recalled that the child fell from a bed onto the floor 3 days prior to surgery. At the time of fall, the parents were able to console the child and did not notice any changes in the child's behavior. The preoperative interviewers did not pose the question of recent trauma to parents and only covered recent illnesses or symptoms related to illness. The patient was closely observed over the next 5 days and discharged to home after 2 weeks.

Figure 1. Thromboelastogram in heparinase cup prior to surgery (baseline).

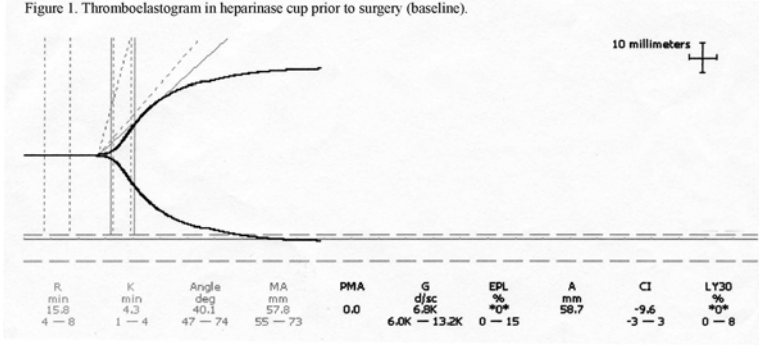


Figure 2. Thromboelastogram from heparinase cup at end of surgery. Test was terminated early at 28 min.

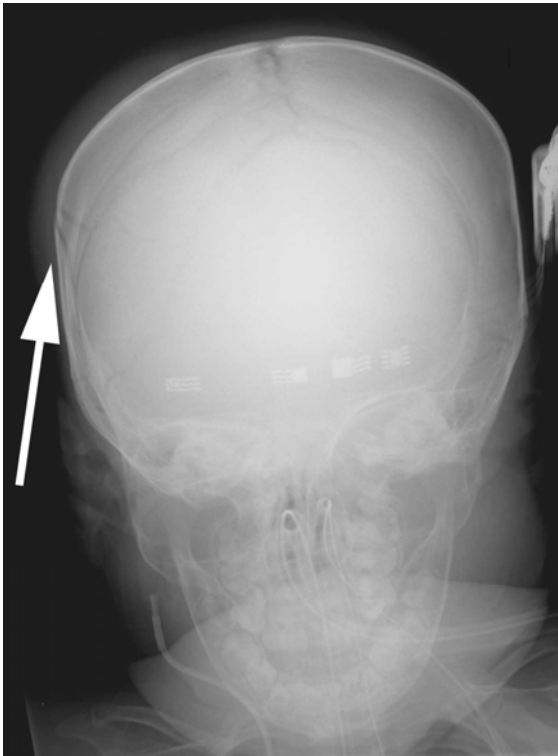
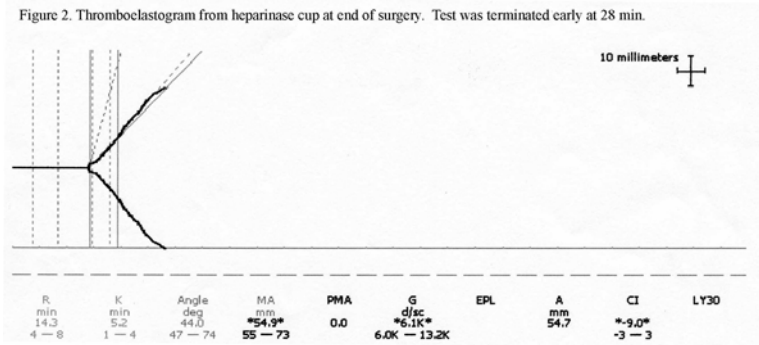


Figure 3. Soft tissue swelling over the right parietal area with a non-depressed skull fracture in the right parietal bone.

Discussion: For surgical cases requiring anticoagulation, specific questioning about recent trauma is indicated even without evidence of trauma on physical examination. This case also suggests that physicians

rethink the safety of anticoagulation even 72 hour after significant closed trauma. For accurate medical histories of pediatric patients, we depend on parents as patients under the age of one year are too young to communicate physical issues.