

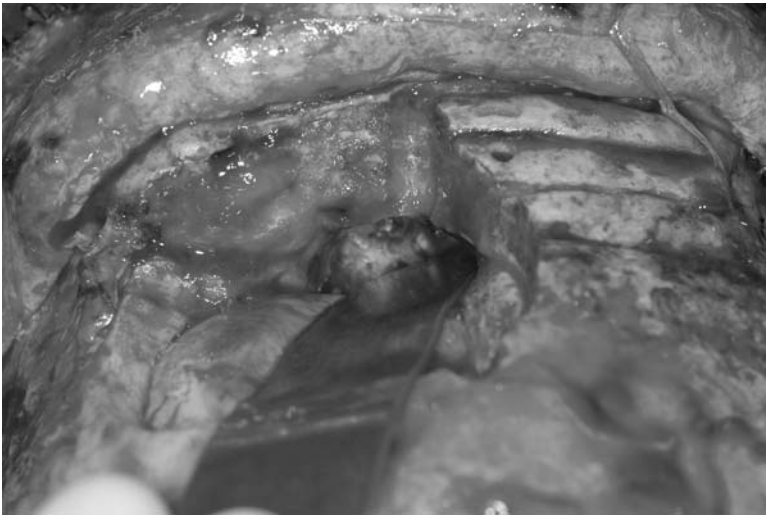
Adult Patients with Congenital Diseases: Where Shall They Go? A Dilemma for Patients and Doctors.

Author(s): PM Meier, MR Proctor, GF Rogers, LR Ferrari

Affiliation(s): Departments of Anesthesiology, Neurosurgery and Plastic Surgery, Children's Hospital Boston and Harvard Medical School, Boston, MA 02115

Introduction: The advances in treatment of congenital diseases in infants have resulted in an improvement in survival rate. Patients with complex congenital problems requiring repeated interventions during infancy and adolescence become very comfortable in the pediatric hospital environment and do not want to switch to adult medical services. Adult clinicians are often reluctant to treat patients with congenital diseases due to a lack of familiarity with them. Pediatric hospitals do not have the capacity, infrastructure and manpower to care for increasing numbers of adult patients. This is a dilemma for clinicians who try to coordinate treatment for these patients due to multiple conflicting policies between the adult and pediatric hospitals. This patient safety issue is compounded by superimposed adult medical comorbidity. As a result, these patients may not receive timely and appropriate medical care. The following case illustrates the variety of problems encountered in patients who may have to bridge two different medical care areas.

Case: A developmentally delayed 44 year old woman with a history of Apert's syndrome underwent midface advancement at eighteen years of age at Children's Hospital Boston (CHB). Several years later, she was diagnosed with an encephalocele extending into her nasal region on an MRI at another hospital. She was not referred back to CHB, as the adult clinicians, who lacked craniofacial expertise, thought the encephalocele repair was associated with unacceptable risk. She experienced many years of rhinorrhea, and then developed a near fatal bacterial meningitis. She was successfully treated with antibiotics at an adult facility, and then referred to an adult neurosurgical service. The adult neurosurgeons felt that they lacked the expertise to handle this case because of its unusual and difficult craniofacial anatomy, and she was referred to CHB. After time consuming, extensive discussions and arrangements, it was determined that the surgery would be completed at CHB with postoperative admission to the Intensive Care Unit at the adjoining adult facility. Complete neurosurgical work up was required at the pediatric and adult surgical facilities to comply with the two different hospital documentation requirements. The patient was taken to the operating room of CHB and had an uneventful 4 hour procedure. The pediatric team consisted of a plastic surgeon, neurosurgeon and neuroanesthesiologist. The pediatric anesthesia team anticipated possible difficult intubation but direct laryngoscopy revealed a grade 2 airway so the standard approach was successful. Appropriate monitoring and lines were placed without difficulty. The patient underwent a left frontal craniotomy with repair of a 2 x 2 cm defect in the floor of the left frontal fossa with a large left frontal encephalocele using split –thickness bone graft and a vascularized pericranial flap (see picture).



The patient tolerated the procedure well under a general, opioid based anesthesia. The sedated, intubated patient was transported across a bridge to the adult neurosurgical intensive care unit. On arrival there the team had to switch monitors to comply with the available monitoring capabilities. After report was given to the adult ICU team, the patient was extubated by the pediatric anesthesia team but the presence of the extubation service of the adult hospital was required. For the overnight ICU stay the pediatric neurosurgical/craniofacial team required additional coverage by the adult neurosurgical service. The patient was discharged from the ICU to the inpatient floor on the following day, and discharged from the hospital on POD 2. At the 4 week follow up evaluation the patient had good wound healing, resolution of rhinorrhea, and began to resume normal activity.

Discussion: The increasing number of patients with congenital diseases surviving childhood requires physicians who are familiar with the congenital diseases and the adult medical comorbidities. The patient described had a near fatal bacterial meningitis from a known condition before treatment was successfully achieved by the coordinated approach of pediatric and adult caretakers. More common is the increasing population¹ of children who have undergone successful repair or palliation of congenital heart disease (CHD). 40,000 children are born with cardiovascular anomalies each year and approximately 85% of those babies can now expect to reach adulthood². The majority, if not all patients with CHD, requires long-term surveillance, and many need re-operation. This can be more than 300,000 patients over the next 10 years for this one congenital disease only. This heterogeneous population requires physicians to have specific knowledge, expertise, and technical skills, to manage the wide variety of diagnoses and pathophysiology of congenital diseases, a potential new subspecialty. A possible solution for the organizational dilemma between pediatric and adult care givers and the superimposed safety issues might be a special floor for adult patients with former congenital diseases in a children's hospital or a special floor in an adult hospital which meets the needs of these adult patients and the competence to deal with former congenital pediatric diseases.

Ref: 1. Warnes CA, Deanfield JE: Congenital heart disease in adults, Hurst's the heart, 10 Edition. Edited by Fuster V, Alexander RW, O'Rourke RA. New York, McGraw-Hill, 2001, pp 1907-19382.
2. Moller J.H. et al. Circulation 1994; 89: 923-30